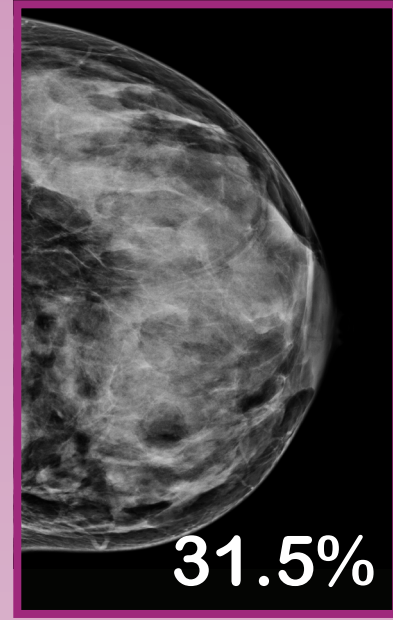
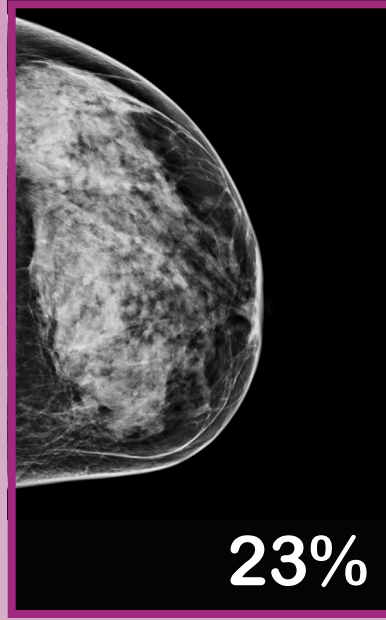
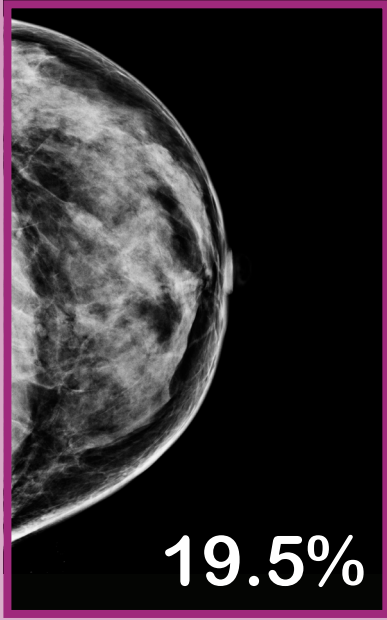


Volumetric Breast Density Scale

DENSE

NON-DENSE

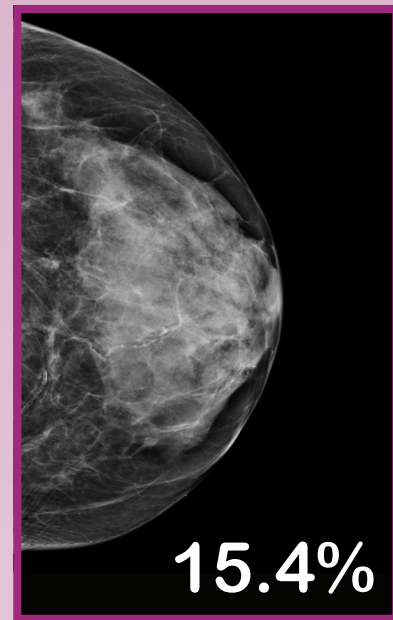
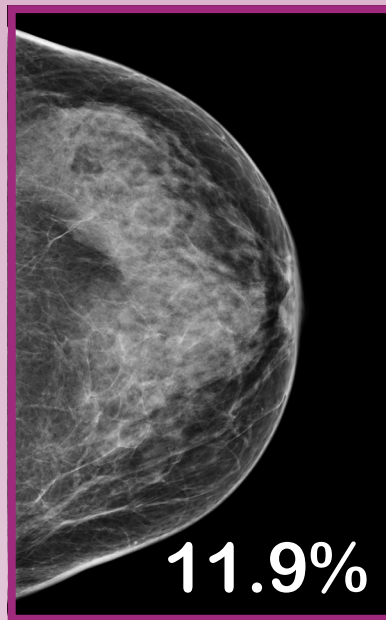
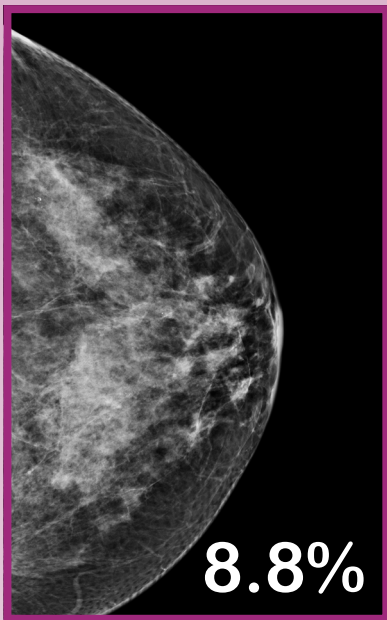
The breasts are extremely dense, which lowers the sensitivity of mammography



d

15.5

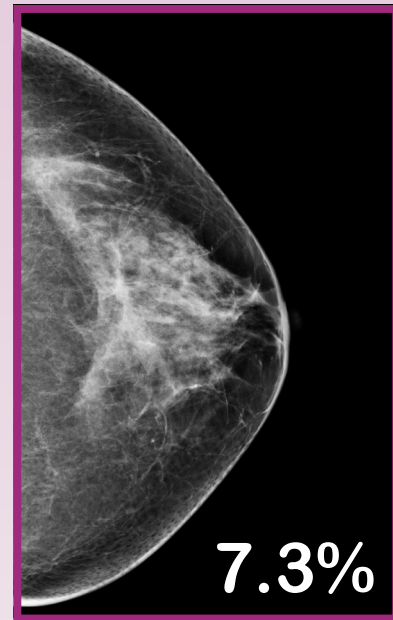
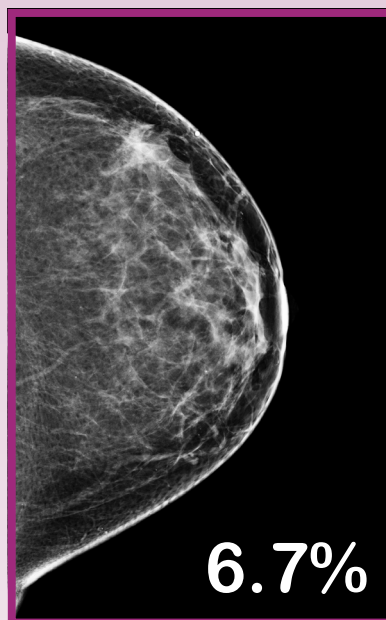
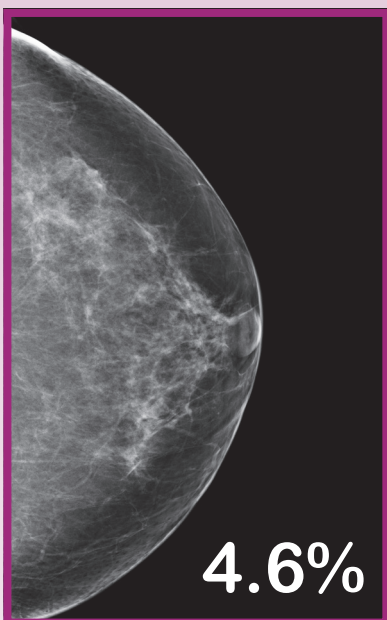
The breasts are heterogeneously dense, which may obscure small masses



c

7.5

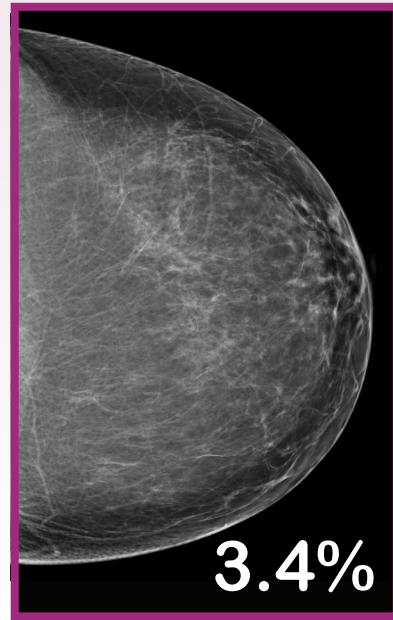
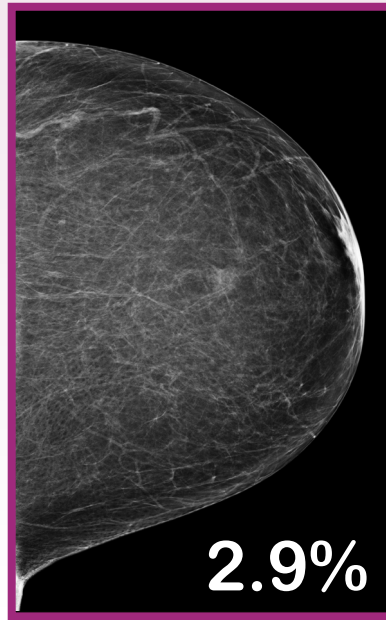
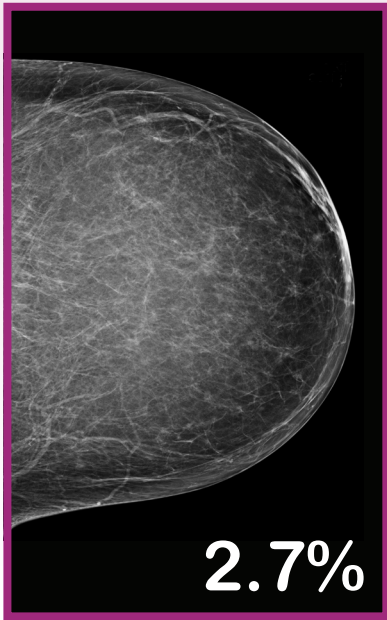There are scattered areas of fibroglandular density



b

3.5

The breasts are almost entirely fatty



a